



ADVANCING EXCELLENCE IN SEXUAL
AND GENDER MINORITY HEALTH

Sexual Health for Trans and Gender Diverse People

.....

Asa Radix, MD, PhD, MPH, FACP

Callen-Lorde Community Health Center

March 20-22, 2020



NATIONAL LGBT HEALTH
EDUCATION CENTER

A PROGRAM OF THE FENWAY INSTITUTE



HARVARD
MEDICAL SCHOOL

Disclosure

- I have no relevant financial, professional or personal relationships to disclose
- This presentation includes slides of genitalia & skin lesions

Learning Objectives

Upon completion of this presentation, learners should be better able to:

- Review terminology related to transgender health care
- Describe the epidemiology of STIs among transgender people
- Review diverse guidelines on how to apply gender- and anatomy-based recommendations to patients of transgender experience



CDC STD Guidelines 2015

Transgender Men and Women

Clinicians should assess STD- and HIV-related risks for their transgender patients based on current anatomy and sexual behaviors



Case 1

26 year old Latina trans woman with intermittent vaginal bleeding/pain for 4 months

PMH: Estrogen therapy since age 20

PSH: penile inversion vaginoplasty age 21 (Thailand)

She works as a nanny, has no health insurance, not a legal resident



Exam: Watery discharge, dime sized white plaque noted



Questions

- What is your differential?
- What tests would you obtain?
- Why did she wait 4 months with bleeding and pain before seeing a provider?



Case 1 cont

Testing

- Vaginal swabs for GC/CT
- Vaginal swabs for trich, candida, HSV
- Wet mount
- RPR
- HIV screen

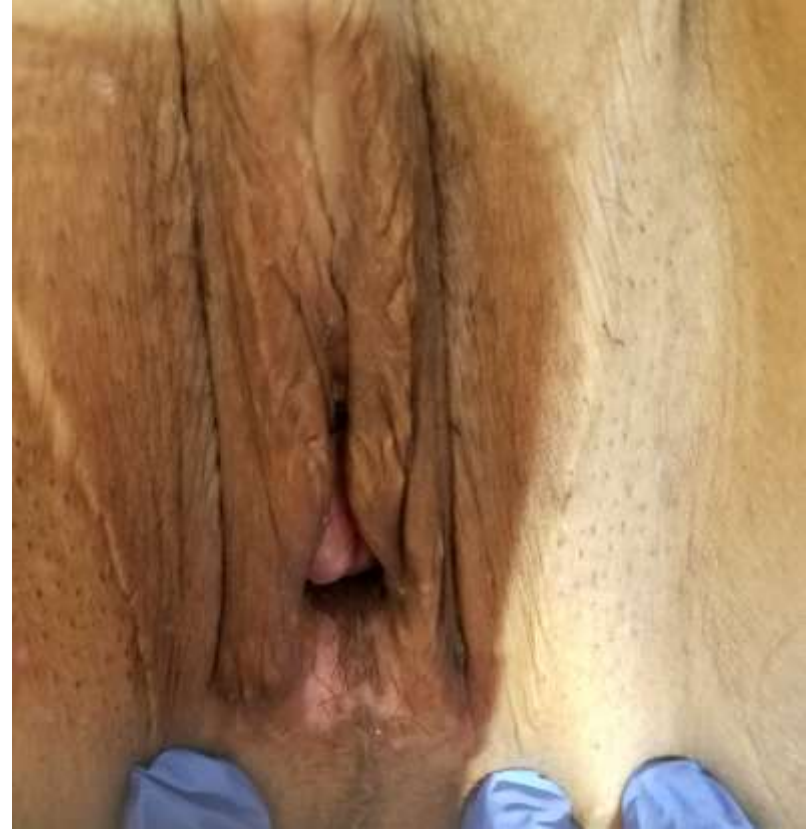

Herpes Virus I/II DNA (Collection Date: 09/04/2018 17:07, Status: Final)

| Component | Result | Units | Flag | Range |
|-----------|----------|-------|------|----------|
| HSV-1 | Negative | | | Negative |
| HSV-2 | Positive | | A | Negative |

Bacterial Vaginosis Screen, DNA - BD AFFIRM (Collection Date: 09/04/2018 17:07, Status: Final)

| Component | Result | Units | Flag | Range |
|------------------|----------|-------|------|----------|
| CANDIDA, DNA | NEGATIVE | | | NEGATIVE |
| GARDNERELLA, DNA | NEGATIVE | | | NEGATIVE |
| TRICHOMONAS, DNA | NEGATIVE | | | NEGATIVE |



After treatment with valacyclovir



ADVANCING EXCELLENCE IN SEXUAL
AND GENDER MINORITY HEALTH

Transgender Women and STIs

- No national surveillance data (often counted as MSM)
- STI data
 - Increased VDRL seropositivity compared with cis-MSM (India, Peru) and non-trans (India)
 - Increased prevalence GC/CT compared with cis-MSM (USA, Peru)
 - Increased rates of HPV, Hepatitis B & C, HSV compared with cis-MSM (Peru)
- Neovaginal risk (HIV) not known
- Limited data for transgender men/nonbinary people

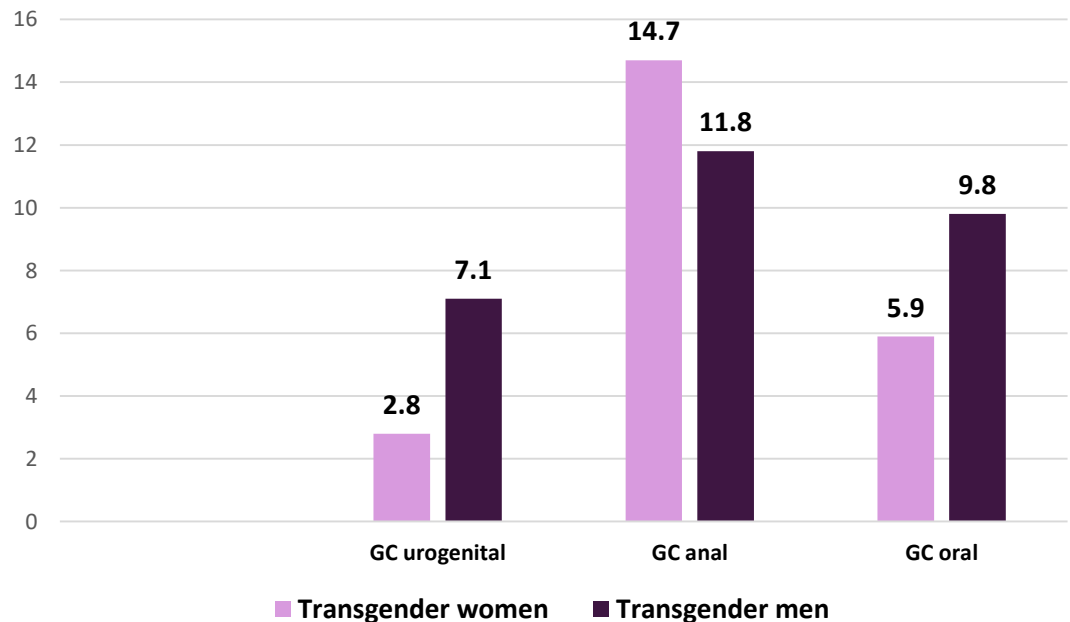
Gupta *STD* 2011, Shrivastava *J Res Health Sci* 2012;Toibaro, *Medicina* 2009; Nuttbrock *AJPH* 2013; Allan-Blitz, *Int J STD AIDS* 2018; Silva-Santisteban *AIDS Behavior* 2012



STIs in Transgender People

- STD Surveillance Network (6 clinics with > 25 TG pts)
 - 506 TW, 120 TM
 - Low rates of extragenital testing (62% TW, 48% TM)

Gonorrhea by site (%)




Pitasi et al, *STD* 2019

Patients' Fears

- Being turned away, refused care or treated differently
- Having to teach providers about trans people
- Being asked unnecessary questions
- Being ridiculed
- Being assaulted by staff or other patients
- Being misgendered

Adapted from the 2015 US Trans Survey



HIV/STI Risk Assessment

Most people have moved past having just 5, but the “Ps” vary

- **Pronouns:** What are your pronouns? What name do you use?
- **Partners:** What are the genders of your partners? How many partners in the last 3 months?
- **Parts:** What words do you prefer to use for your body parts? What bottom surgeries have you had?
- **Practices:** What kinds of sex are you having? Which behaviors might expose you to your partners' fluids?
- **Protection:** How do you protect yourself against HIV and STIs?
- **Past history** of STIs

Examinations

- **Defer unnecessary questions and exams**
 - Build rapport before performing genital exams
 - Avoid satisfying your curiosity (ie, do you really need to know/see?)
- **Conduct sensitive genital exams only when necessary**
 - Always explain the purpose of the exam
 - Use gender neutral terms
 - Ask patients what words they prefer
- **Acknowledge barriers and offer solutions**
 - Stress of stigma and discrimination
 - Limitations of medical knowledge



Vaginoplasty

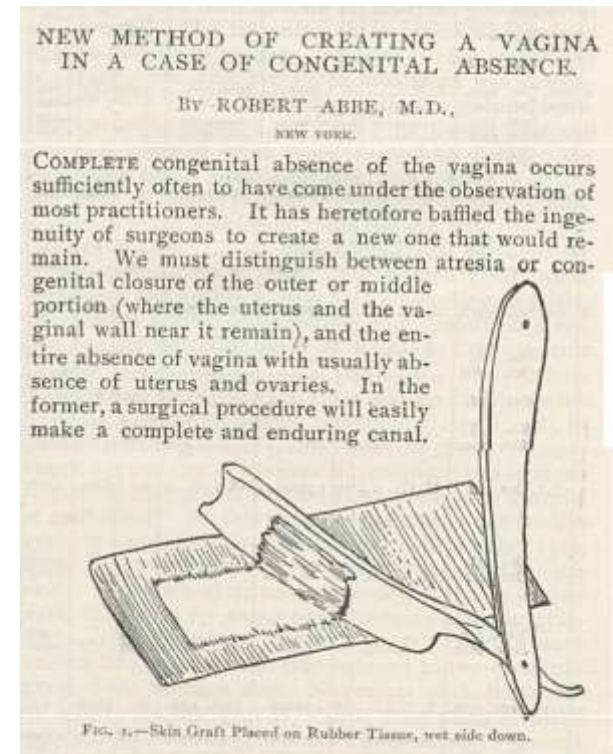
What Primary Care Providers Need to Know



ADVANCING EXCELLENCE IN SEXUAL
AND GENDER MINORITY HEALTH

Vaginoplasty Procedures

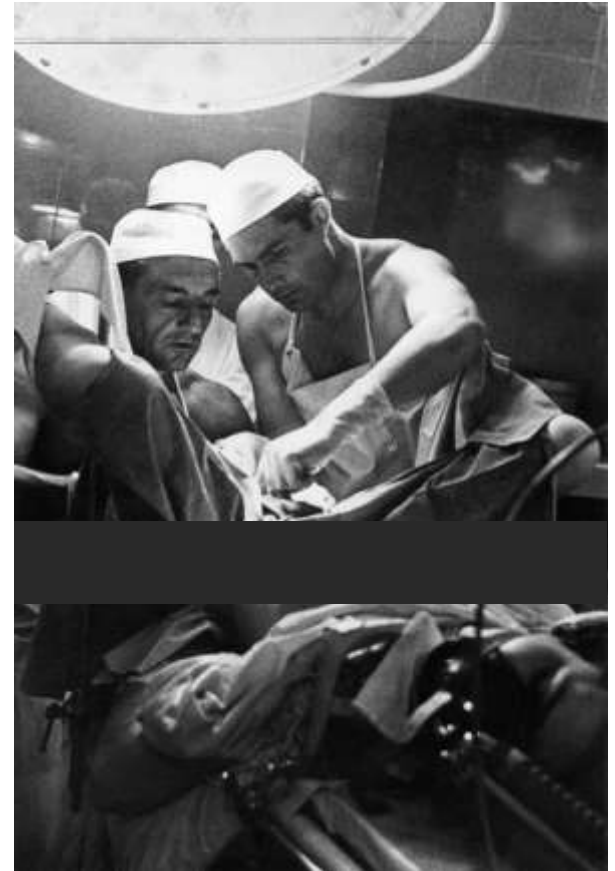- Non-genital skin grafts (1938)
- Penile skin graft (1956)
- Intestinal graft (1974)
- Peritoneal graft (Davydov) 2018



R. Abbe, Medical Record, 1898; Banister and McIndoe, Proceedings of the Royal Society of Medicine, 1938; Markland and Hastings, Journal of Urology, 1974; Bizic et al, Scientific World Journal, 2014; Jalalizadeh M, Shobeiri SA. Female Pelvic Med Reconstr Surg. 2018

Vaginoplasty Procedures

- Non-genital skin grafts (1938)
- Penile skin graft (1956)
- Intestinal graft (1974)
- Peritoneal graft (Davydov) 2018



R. Abbe, Medical Record, 1898; Banister and McIndoe, Proceedings of the Royal Society of Medicine, 1938; Markland and Hastings, Journal of Urology, 1974; Bizic et al, Scientific World Journal, 2014; Jalalizadeh M, Shobeiri SA. Female Pelvic Med Reconstr Surg. 2018



ADVANCING EXCELLENCE IN SEXUAL
AND GENDER MINORITY HEALTH

Vaginoplasty

- Electrolysis or laser
 - Start 3-6 months before
 - Not within 2 weeks of surgery
- VTE prophylaxis
- Vaginal packing removed day 5-6
- Douching (saline or dilute povidone–iodine)
- Initiate dilations

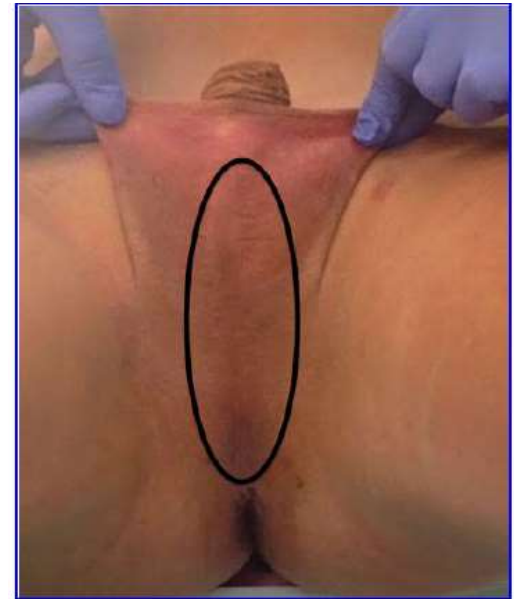
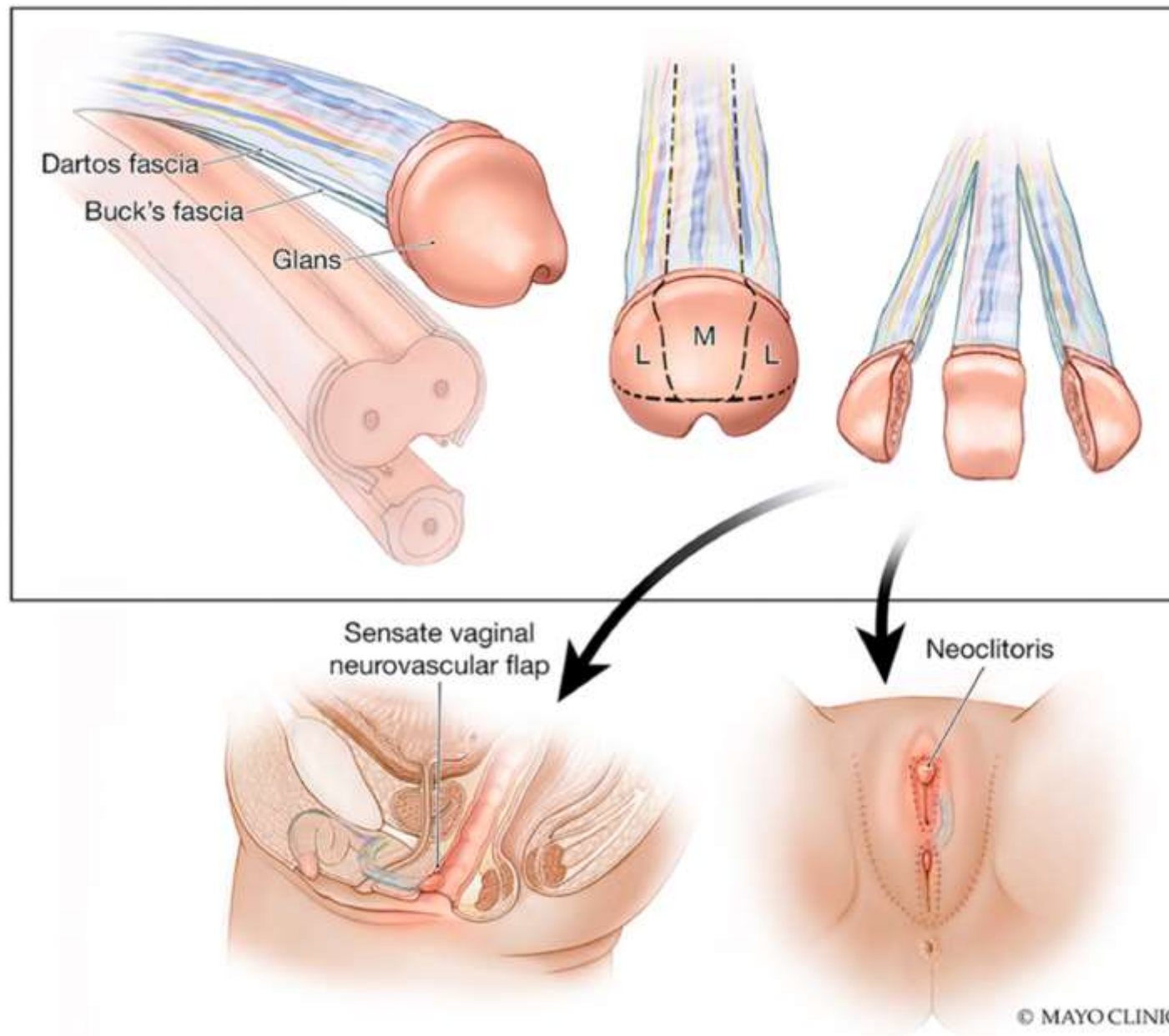


FIG. 1. Approximate area of depilation for scrotoperineal flap.

Schecter, L. Transgender Health, 2016

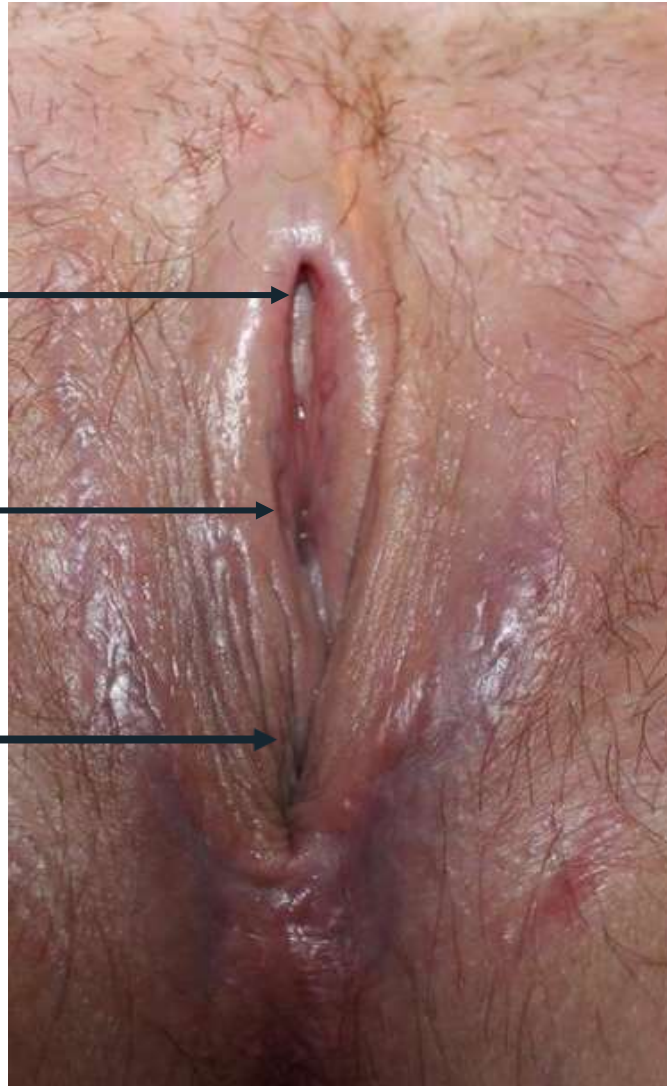


Stowell JT, *Abdom Radiol* (NY). 2020

Neo-clitoris

Urethra

Introitus



6 weeks
post-op

Image: <http://marcibowers.com/mtf/mtf-services/grs>

Post-op Care

- Dilators 2-3 times daily for the first month
- Generally life-time
- Many (56%) use douches
 - iodine solution, low pH douch, tap water



Image: <https://www.pelvicrelief.co.uk/product/soul-source-grs-vaginal-dilators-copy>

Post-Vaginoplasty Complications

- Recto-vaginal Fistula
 - Occurs in up to 1/400 vaginoplasties
 - Anorectal USG/CT/MRI for confirmation
 - Requires surgical repair with skin grafts
- Vaginal stenosis
 - Often related to under-dilation
 - Can using xylocaine 2% jelly and gradually work up with the dilators.
 - Re-teach the correct method to use dilators, lubrication
- Granulation tissue aggregation
 - bleeding and discharge, odor
 - silver nitrate cauterization
- Vaginal prolapse
- Wound dehiscence



Primary care recommendations

- **Comprehensive sexual health history**
- **Assess for symptoms**
 - Comfort with dilation
 - Sensation
 - Depth
 - Coitus
 - Urinary control
 - Rectal sphincter control
 - Discharge/bleeding
 - Sexual activity (pain, bleeding, sensation, orgasm)
- **Exam and STI screening**
 - STIs frequently asymptomatic
 - Screen all exposed sites



Neovaginal exams – How should we do them?

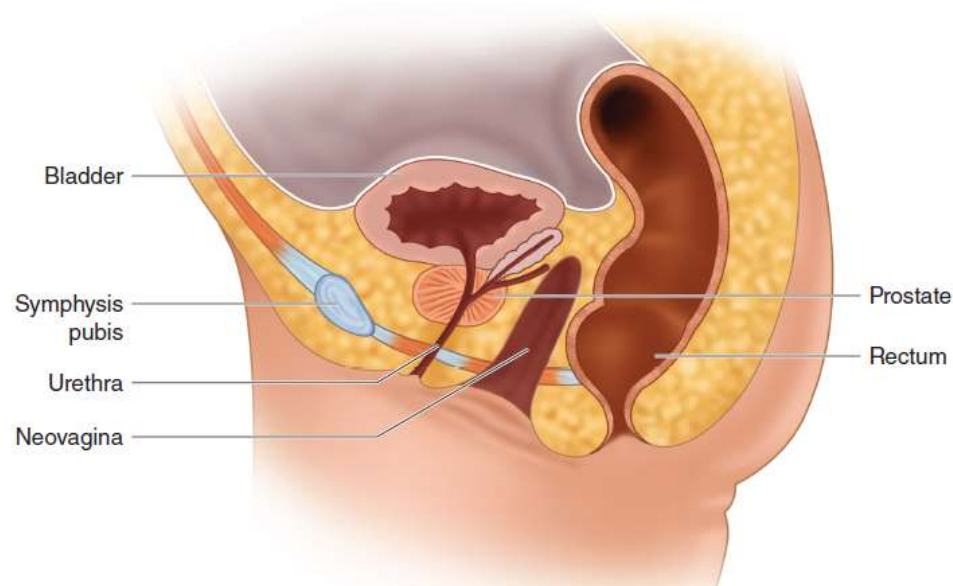
Most TW think exams are important, but <5% routinely are examined after surgery

- Many (56%) use douches – iodine solution, low pH formulas, plain water
- One in 4 bad odor/discharge
- 25% will require smaller speculum (2cm width)
- May need to use anoscope

Matsuki, S., Int J STD AIDS, 2015; Yang, C., Int J STD AIDS, 2009; Jain, Int J STD AIDS, 2007; van der Sluis, W.B., Int J STD AIDS, 2015; Bodsworth, Sex Transm Dis, 1994; Weyers, ObGyn 2010



Neovaginal Exam



- Examine neovagina with anal or small vaginal speculum
- Look for granulation tissue, warts, lesions
- Prostate is palpable at the anterior neovaginal wall

Illustration: Poteat & Radix, Transgender Individuals. In Sexually Transmitted Infections in HIV-Infected Adults and Special Populations. Laura Bachman (ed). 2017 Springer

Case 2

38 y/o African American transgender woman with 3 months of vaginal discharge

PMH: 2 years prior underwent penile inversion vaginoplasty in New York. Initially douched with betadine, then tap water daily. Dilates currently 2x week

Meds: estradiol 2mg daily

(Seen by gynecologist)

Exam: Profuse watery discharge, no lesions

Vaginal swabs – negative for GC/CT

Vaginal swabs negative trich, candida, HSV

Wet mount – no lactobacilli

Bacterial culture done...



SITE: VAGINAL

ORGANISM #1: FEW COLONIES OF ENTEROCOCCUS FAECALIS
ENTEROCOCCI SUSCEPTIBLE TO PENICILLIN ARE PREDICTABLY SUSCEPTIBLE TO
AMPICILLIN, AMOXICILLIN, AMPICILLIN-SULBACTAM, AMOXICILLIN-CLAVULANATE,
PIPERACILLIN, AND PIPERACILLIN-TAZOBACTAM FOR NON-B-LACTAMASE-PRODUCING
ENTEROCOCCI.
ORGANISMS THAT ARE SUSCEPTIBLE TO TETRACYCLINE ARE ALSO CONSIDERED
SUSCEPTIBLE TO DOXYCYCLINE AND MINOCYCLINE.

ORGANISM #2: HEAVY GROWTH OF BETA HEMOLYTIC STREP, GROUP B
FOR GBS, PENICILLIN IS SURROGATE FOR AMPICILLIN, AMOXICILLIN,
AMOXICILLIN-CLAVULANIC ACID, AMPICILLIN-SULBACTAM, CEFAZOLIN, CEFEPIME,
CEFTAROLINE, CEPHRADINE, CEPHALOTHIN, CEFOTAXIME, CEFTRIAXONE,
CEFTIZOXIME, IMIPENEM, ERTAPENEM, AND MEROPENEM. ERYTHROMYCIN AND
CLINDAMYCIN ARE TESTED TO DETECT INDUCIBLE RESISTANCE TO CLINDAMYCIN
(DTEST) BUT ONLY CLINDAMYCIN SHOULD BE REPORTED.

ORGANISM #3: HEAVY GROWTH OF E. COLI
RESULTS OF AMPICILLIN TESTING CAN BE USED TO PREDICT RESULTS FOR
AMOXICILLIN.

CEFAZOLIN RESULTS PREDICT RESULTS FOR THE ORAL AGENTS CEFACLOL,
CEFDINIR, CEFPODOXIME, CEFPROZIL, CEFUROXIME, CEFPHALEXIN, AND
LORACARBEF.

ORGANISMS THAT ARE SUSCEPTIBLE TO TETRACYCLINE ARE ALSO CONSIDERED
SUSCEPTIBLE TO DOXYCYCLINE AND MINOCYCLINE.

ENTEROCOCCUS FAECALIS

| Drug | MIC | Interps |
|----------------|--------|---------|
| GENT. SYNERGY | <=500 | S |
| LINEZOLID | 2 | S |
| PENICILLIN | 2 | S |
| STREP. SYNERGY | <=1000 | S |
| TIGECYCLINE | | S |

BETA HEMOLYTIC STREP, GROUP B

| Drug | MIC | Interps |
|--------------|-----|---------|
| CLINDAMYCIN | | S |
| LEVOFLOXACIN | | S |
| PENICILLIN | | S |
| VANCOMYCIN | | S |

Culture - Enterococcus faecalis (few), Beta hemolytic Strep Group B (heavy growth), E.

Treatment Course

- Gynecologist placed patient on amoxicillin-clavulanate tablets, advised to resume betadine douches
- Symptoms continued, pt received 2 courses of quinolones after cultures persistently positive for *E. coli* and *E. faecalis*
- Referred to our clinic for “recurrent infection”
- When should you perform exams after surgery?
- What is the usual neovaginal microbiome?
- Does she need treatment?



Neovaginal Microbiome

- Average pH of the neovagina is pH 5.88 (5-7) cis women 4-4.5
- Lack of lactobacillus spp
- **(Penile-inversion)** Mixed microflora
 - >70 species of bacteria - Enterococcus faecalis, bacteroides, fusobacteria, staph strep & BV-associated bacteria (Atopobium vaginae, Gardnerella vaginalis, Mobiluncus curtisii)
- **(Intestinal)**
 - E. coli, Proteus, Providencia, Strep, Bacteroides, staph

Matsuki, S., Int J STD AIDS, 2015; Yang, C.,. Int J STD AIDS, 2009;Jain, Int J STD AIDS, 2007; van der Sluis, W.B., Int J STD AIDS, 2015;Bodsworth, Sex Transm Dis, 1994; Weyers, S., BMC Microbiol, 2009.Toolenaar J Clin Micro 1993; Weyers BMC Micro 2009

Case 3

65 year old white transgender woman, sudden onset of vaginal bleeding with dilations. She is married to a cis-gender man. Never uses condoms. Vaginal sex only

PSH: 24 years before had vaginoplasty (intestinal)

Not sexually active

Dilates 4-5 times per week

Estradiol patches, 100 mcg/daily

Neovaginal Bleeding

- What is your differential? Could this be an STI?
- Should you do a vaginal exam?
- What testing should you do?



Neovagina, intestinal

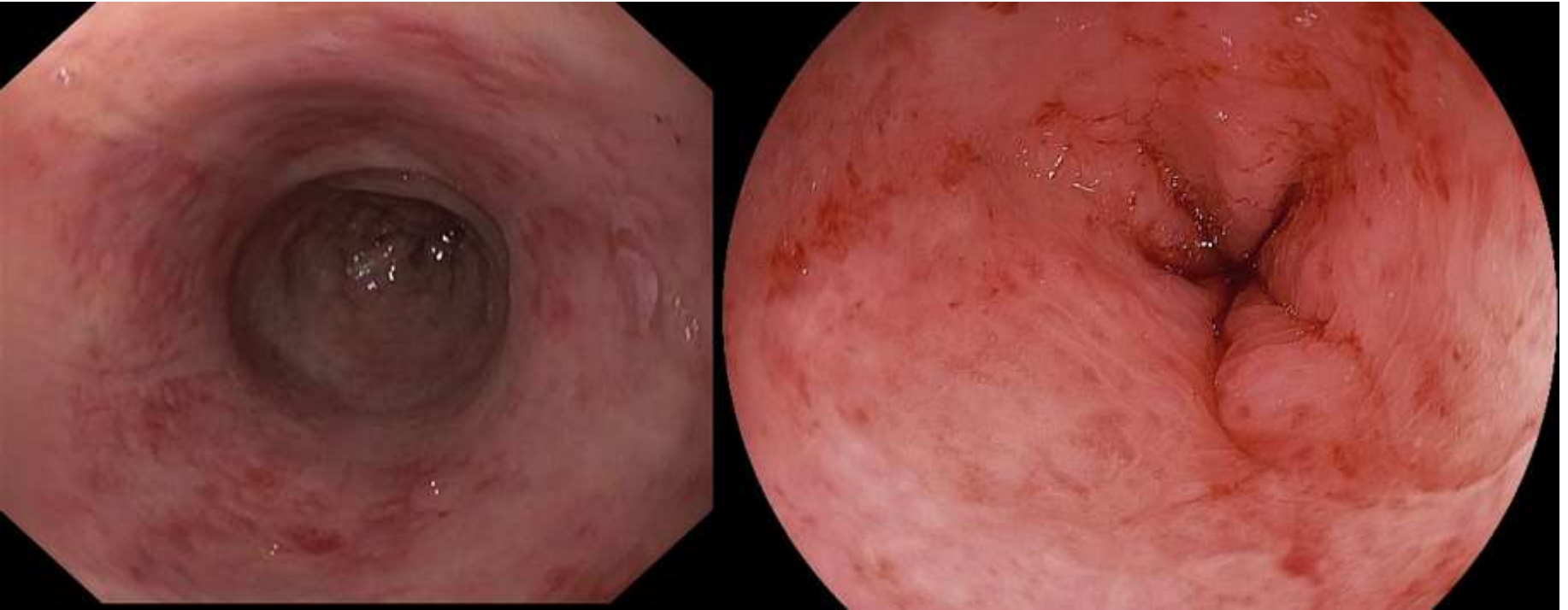


Image: van der Sluis, *J Sex Med*
2016;13:702e710

Differential diagnosis of bleeding after vaginoplasty

Colo-vaginoplasty

Diversion colitis

Mucosal atrophy

STIs

Trauma

Polyps

Adenocarcinoma

Inflammatory bowel disease

Post-operative bleeding

Penile-inversion

STIs

Trauma

Squamous cell carcinoma

Post-operative bleeding

Case 4

36 year old African-American transgender woman. New sexual partner, cis-male

- **Increase in vaginal discharge and odor**
- No condoms for sex

PSH: 4 years before had vaginoplasty (penile inversion) using peritoneal grafts (Davydov procedure)

She's worried she might have STI

What factors might increase her risk for STIs?

What types of neovaginal STIs have been reported?

How should you screen for STIs?

How would you counsel her about STI prevention?

- Vaginal swab PCR positive *C. trachomatis*
- Repeat testing negative 4 weeks after treatment

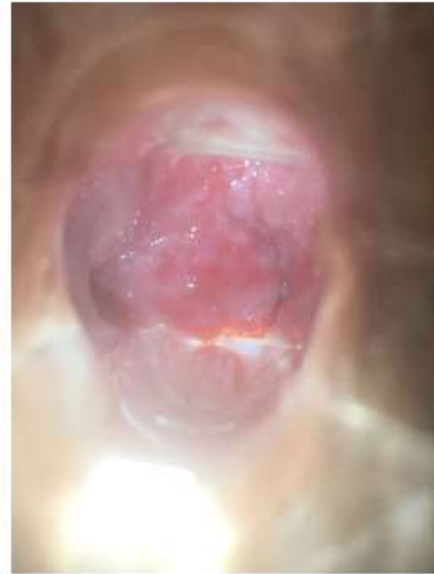

Image: Callen-Lorde CHC 2017

Neovaginal STIs

- Condyloma acuminatum
- Neisseria gonorrhoeae (often asymptomatic)
- Chlamydia trachomatis
- HSV
- No case reports of Trichomoniasis

Conditions that can mimic STIs

- Fistulae
- Granulation tissue
- Folliculitis / retained hairs

Matsuki, S., Int J STD AIDS, 2015; Yang, C.,. Int J STD AIDS, 2009;Jain, Int J STD AIDS, 2007; van der Sluis, W.B., Int J STD AIDS, 2015;Bodsworth, Sex Transm Dis, 1994; Weyers, S., BMC Microbiol, 2009; Radix Open For Inf Dis 2019

STI Screening for Transgender Women

- **Always take an anatomic inventory**
 - What surgeries were done?
 - What organs are still present?
- **Vaginoplasty**
 - Speculum exam
 - NAAT testing GC/CT



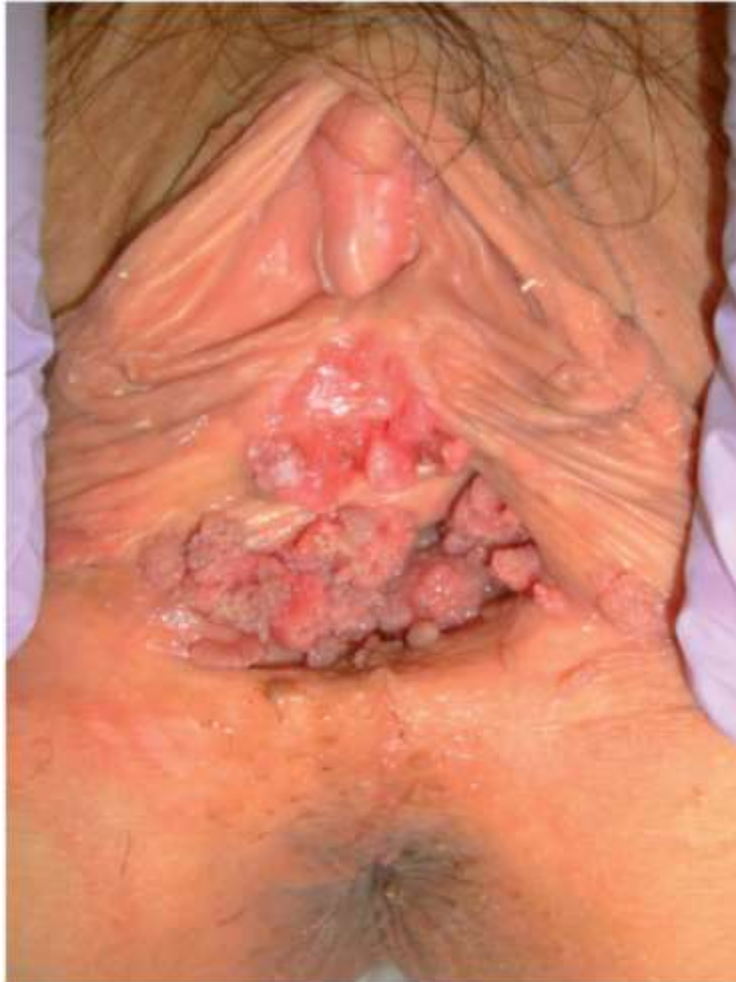

Image: Matsuki, Int J STD AIDS. 2015 Jun;26(7):509-11

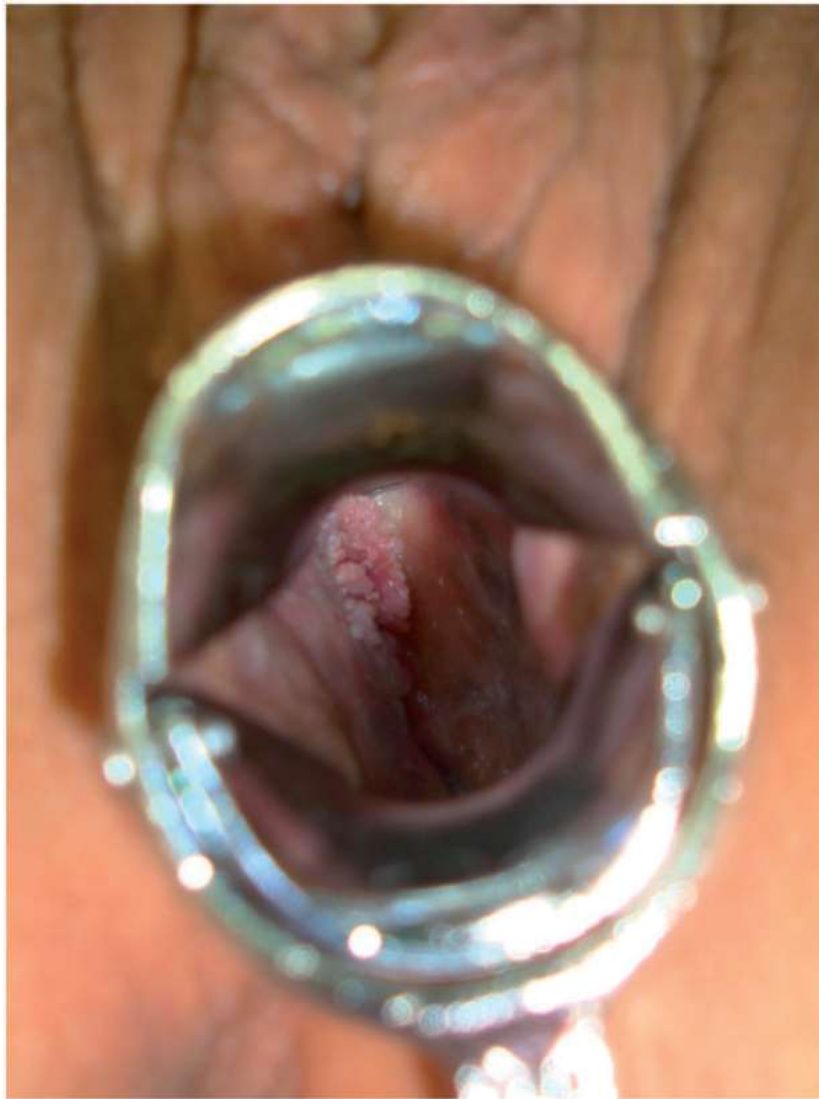

Image: Matsuki, Int J STD AIDS. 2015 Jun;26(7):509-11

Case 5

38 year old white transgender man presents with 4 days burning on urination and lower abdominal cramping "I was exposed to gonorrhea"

- Condomless sex with cis-male partner 4 days prior
- PSH:
- Metoidioplasty in Serbia 5 years prior
- Top surgery age 24
- PMH:
- Socially transitioned at age 20, on hormones since age 22
- Meds: transdermal testosterone



Case

- Urine and anal GC/CT, RPR
- HIV rapid negative
- Received ceftriaxone/azithromycin



Clinical Questions

- Does his surgery (metoidioplasty) change the clinical evaluation?
- What is the impact of testosterone on susceptibility of STIs? Fertility?
- How does testosterone administration impact preventive care recommendations (cervical screening)
- What other diagnostic tests should you consider?

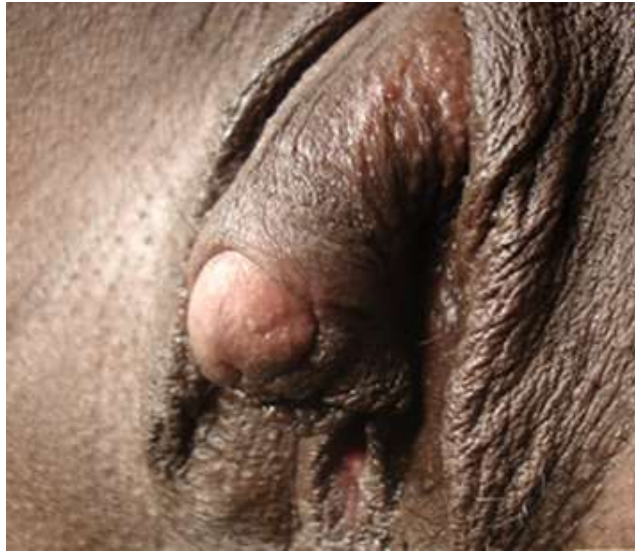


Clinical Issues

- Ask client exactly what surgeries were performed
“anatomic inventory”
- Uterus – is he pregnant?
- Cervix can be retained – cervical cancer screening
according to standard guidelines
- STI screenings based on behavior/anatomy

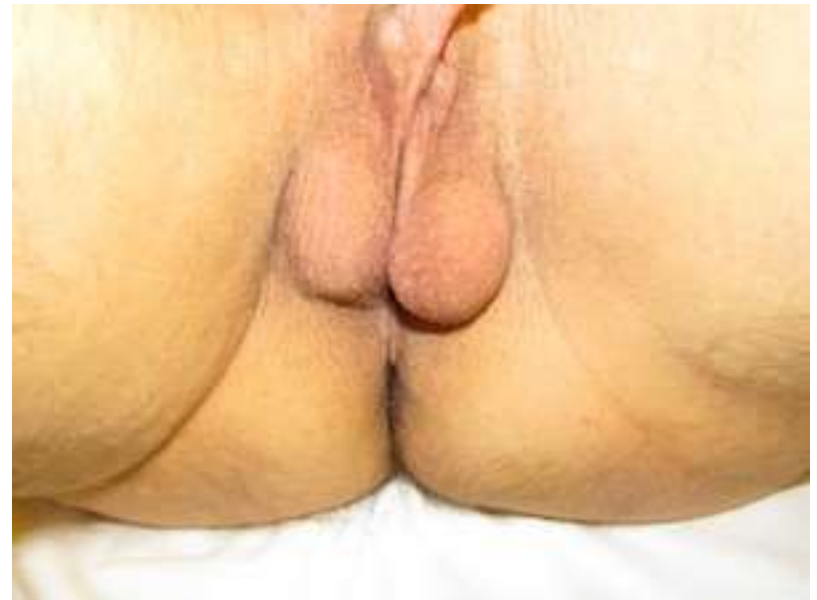Metoidioplasty (meta)

- Release of the clitoris/phallus from the labia minora
- May include urethroplasty (why is it important to know this?)



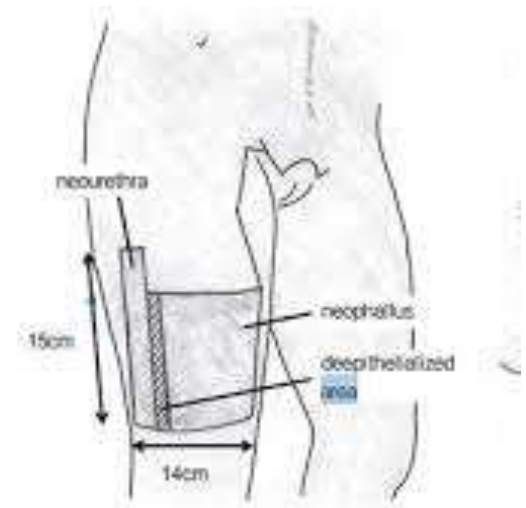
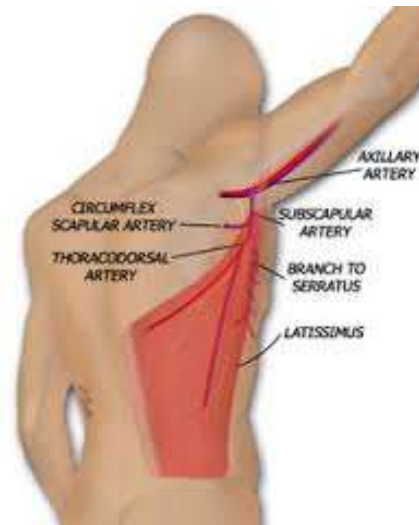
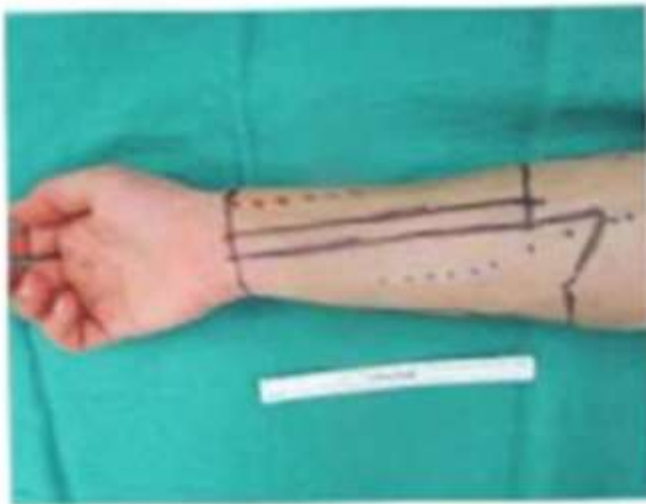
Other procedures

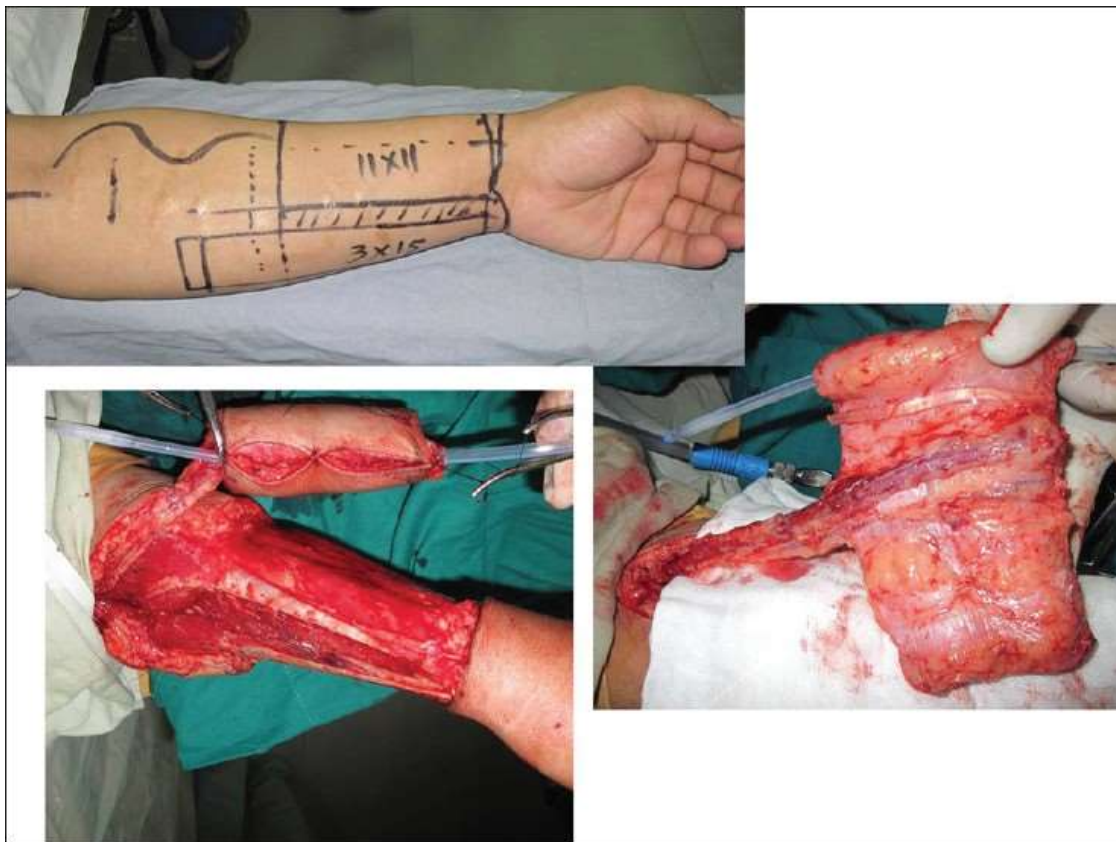
- Vaginectomy / colpoclesis
- Scrotoplasty with testicle implants
 - labia majora united into an approximation of a scrotum.
- Mons reduction



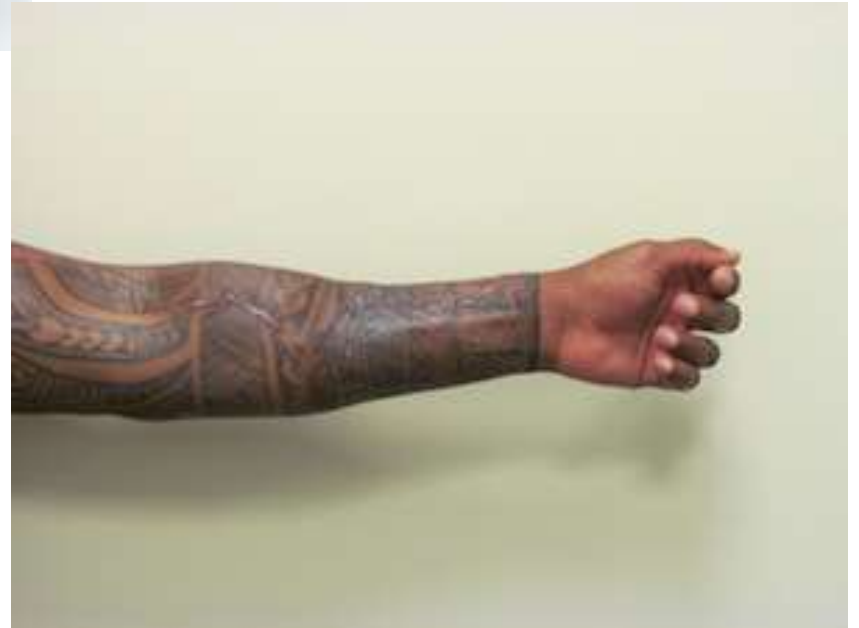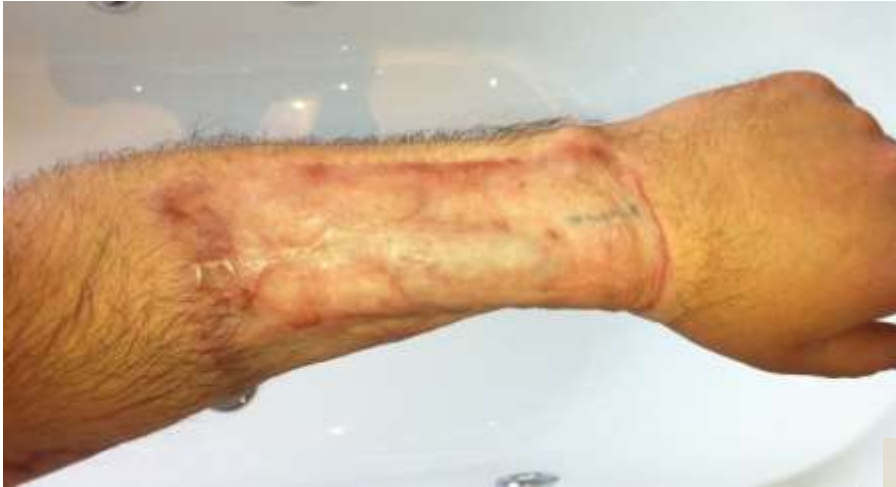Phalloplasty

- Creation of phallus
- Radial forearm
- MLD (musculocutaneous latissimus dorsi flap from the back)
- ALT (anterior lateral thigh flap)





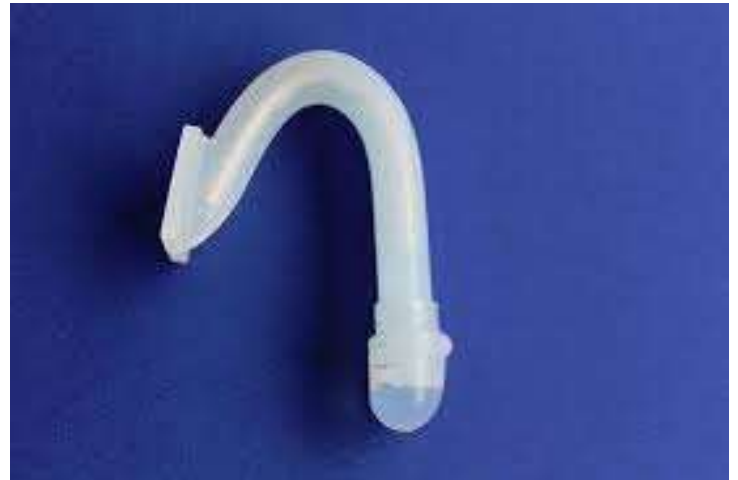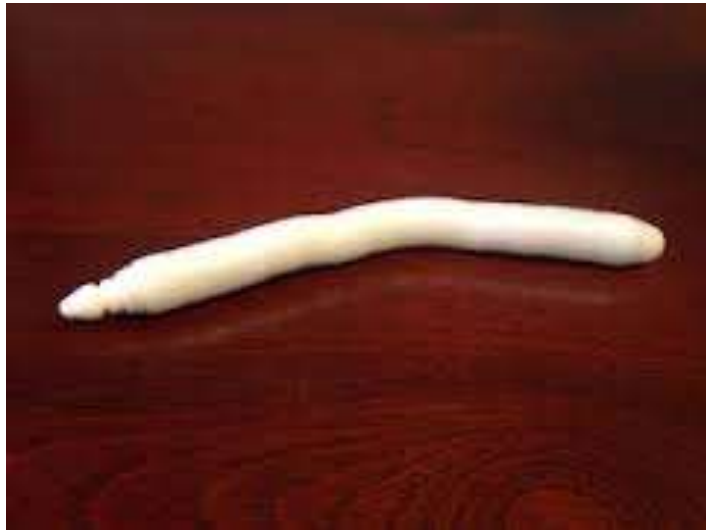ADVANCING EXCELLENCE IN SEXUAL
AND GENDER MINORITY HEALTH



ADVANCING EXCELLENCE IN SEXUAL
AND GENDER MINORITY HEALTH

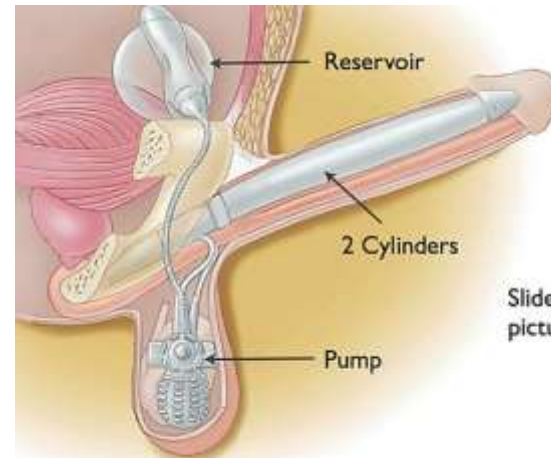
Penile Implants

- Non Inflatable or semi rigid
- Always firm
 - One or two bendable rods.
 - Bend into position, erect, flaccid
- Inexpensive, fewer moving parts



Penile Implants

- Inflatable Penile Implants
- 2-piece, 3-piece (reservoir)
 - inflatable cylinders in the shaft of the penis, and a hydraulic pump providing an erection
 - pump and release valve in the scrotum
- Expensive, 10-yr life span



Slideshow: Inflatable Penile Implant pictures and illustrations

Case 6

A 28-year-old transgender man comes to your clinic for a check up. He is sexually active with cis-gender women and cisgender men

No bottom (genital) surgeries

Meds: testosterone cypionate 100mg IM every week for 10 years

What do we know about cervical screening?

Fertility?

Pap Smears in Transgender Men

Based on study at Fenway Health, Boston

- Transgender men patients may avoid pelvic exams and be less likely to have cervical cancer screening (64% vs. 74%)
- were more likely to have an inadequate Pap, (10.8 % vs 1.3%)
- 20 % inadequate pap if on testosterone >6 months
 - Be sure to inform lab that patient is using testosterone and that it is indeed a cervical specimen
 - If amenorrhea present, indicate on lab requisition

Peitzmeier, Am J Prev Med 2014;47(6):808–812;
Peitzmeier, J Gen Intern Med. 2014 May;29(5):778-84

Alternatives to Pap for Cervical Screening

- Allow self-collection of swabs, including HPV screen in place of cervical cytology specimen
- Perform external or bimanual exam, which may help patient become more comfortable with speculum exam in the future

Transmen and Pregnancy

- Study of 41 TGM
- Identity - 50% male, 24% transgender, 20% GNC
- 5 (20%) conceived while on testosterone
- 32% unplanned pregnancy

Discuss fertility:

Contraception (LARC:DMPA, IUD, implant)

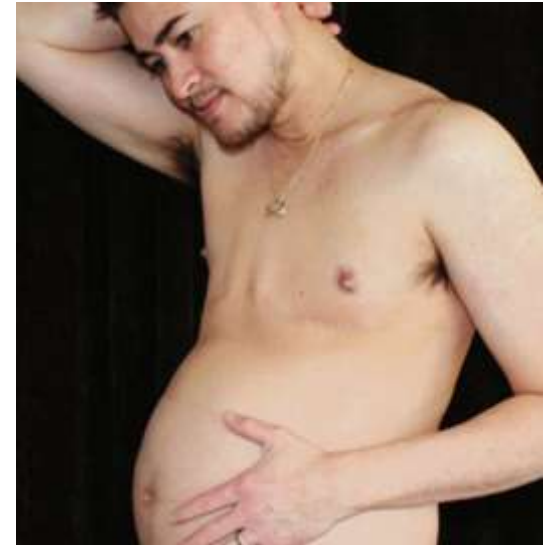

Image: <https://www.ebab.com/gay-travel-blog/category/gay-life>

Light AD, Obedin-Maliver J, Sevelius JM, Kerns JL.

Obstet Gynecol. 2014 Dec;124(6):1120-7



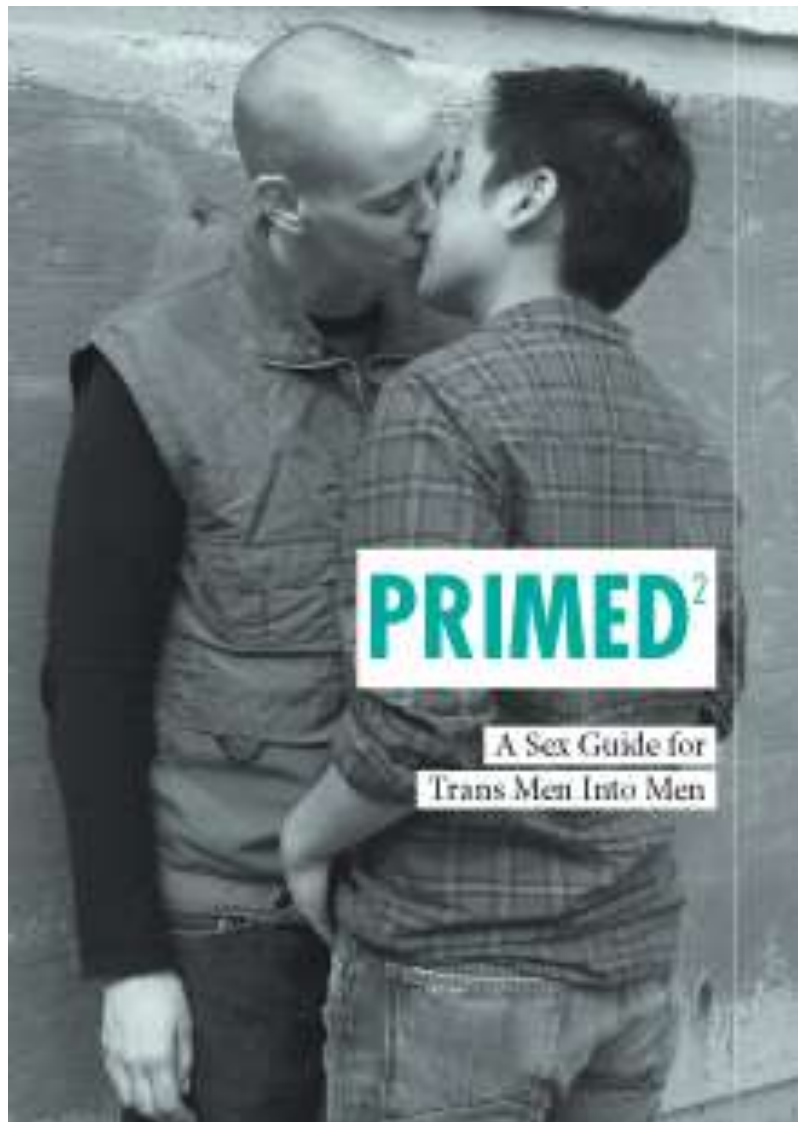
ADVANCING EXCELLENCE IN SEXUAL
AND GENDER MINORITY HEALTH

STI Screening for TM after Bottom Surgery

- Metoidioplasty or phalloplasty
 - Did patient have vaginectomy?
 - Was there urethral lengthening (UL), aka urethral follow through?
- If UL, no vaginectomy
 - Vaginal swabs for GC/CT, Trich, BV
- If no UL – can use urine testing

Summary

- Create welcoming clinical sites that facilitate disclosure of gender identity/sexual orientation
- Ask name, gender and pronoun
- Think about language
- Understand diversity of sexual orientation and behaviors “no assumptions”
- Anatomic inventory “if you have it, check it”
- Outreach in transgender communities
- Appropriate prevention materials & resources



Sources: http://www.queertransmen.org/15gms004_primedguide-redo_vfa4_booklet_eng.pdf

<http://librarypdf.catie.ca/pdf/ATI-20000s/26424.pdf>



ADVANCING EXCELLENCE IN SEXUAL
AND GENDER MINORITY HEALTH

RESOURCES

Endocrine Treatment of Gender-Dysphoric/Gender-Incongruent Persons: An Endocrine Society* Clinical Practice Guideline. J Clin Endocrinol Metab, November 2017, 102(11):1–35

World Professional Association for Transgender Health. Standards of care for the health of transsexual, transgender, and gender nonconforming people, seventh version. September 2011.
http://www.wpath.org/publications_standards.cfm.

Schechter L. Gender Confirmation Surgery:
An Update for the Primary Care Provider. *Transgender Health*.
2016 1(1):32-40



RESOURCES

Fenway Health

www.fenwayhealth.org

Callen-Lorde Community Health Center

<http://callen-lorde.org/transhealth/>

UCSF COE Transgender Health

<http://transhealth.ucsf.edu/>

@asaradix

@callen-lorde



ADVANCING EXCELLENCE IN SEXUAL
AND GENDER MINORITY HEALTH